

Complications of bronchoscopy: A concise synopsis

David L Stahl, Kathleen M Richard¹, Thomas J Papadimos

ABSTRACT

Flexible and rigid bronchoscopes are used in diagnosis, therapeutics, and palliation. While their use is widespread, effective, and generally safe; there are numerous potential complications that can occur. Mechanical complications of bronchoscopy are primarily related to airway manipulations or bleeding. Systemic complications arise from the procedure itself, medication administration (primarily sedation), or patient comorbidities. Attributable mortality rates remain low at < 0.1% for fiberoptic and rigid bronchoscopy. Here we review the complications (classified as mechanical or systemic) of both rigid and flexible bronchoscopy in hope of making practitioners who are operators of these tools, and those who consult others for interventions, aware of potential problems, and pitfalls in order to enhance patient safety and comfort.

Key Words: Bronchoscopy, complications, endoscopy, intensive care

INTRODUCTION

Endoscopic techniques that allow visualization of the airways of patients with pulmonary maladies have become a mainstay of medical treatment. Since the invention of the rigid bronchoscope in 1897 by Gustav Killian, along with its refinement by Chevalier Jackson in the early 20th century, and Shigeto Ikeda's introduction of the flexible bronchoscope in 1967; these instruments have become important clinical assets in the armamentarium of surgeons, intensivists, and pulmonologists.^[1,2] Bronchoscopy, both fiberoptic and rigid, encompasses a number of diagnostic and therapeutic techniques to visualize the luminal surface of the trachea and proximal airways. Flexible or fiberoptic bronchoscopy, allows for excellent visualization of the airway lumen and luminal surface including segmental and subsegmental bronchi with a relatively less traumatic instrument; rigid bronchoscopy enables more therapeutic options but is limited to the trachea and main bronchi unless combined with a fiberoptic bronchoscope.^[1,2] Bronchoscopy has become an important tool not only for visualizing abnormalities, but also for biopsy/tissue sampling, removal of secretions, mucous plugs, clots, and foreign bodies. More recent advances include stent placement for relief of airway compression, laser applications (tumor resection), curtailing hemorrhage (using cryocoagulation/cryotherapy), assisting in the

placement of percutaneous tracheostomies, and securing the airway through facilitation of endotracheal tube placement.

Traditionally, complications of bronchoscopy were labeled minor, major/severe, or fatal. These terms are often nebulous and vary across individuals and institutions. We discuss complications of both flexible and rigid bronchoscopy, categorizing them as mechanical or systemic for improved clarity.

Fiberoptic bronchoscopy

Since its introduction in the 1960s, published rates of complication from fiberoptic bronchoscopy have ranged from <0.1 to 11%, with mortality generally reported between 0 and 0.1%.^[3-10] No definitive

This is an open access article distributed under the terms of the Creative Commons Attribution-NonCommercial-ShareAlike 3.0 License, which allows others to remix, tweak, and build upon the work non-commercially, as long as the author is credited and the new creations are licensed under the identical terms.

For reprints contact: reprints@medknow.com

Cite this article as: Stahl DL, Richard KM, Papadimos TJ. Complications of bronchoscopy: A concise synopsis. *Int J Crit Illn Inj Sci* 2015;5:189-95.

Access this article online

Website: www.ijciis.org

DOI: 10.4103/2229-5151.164995

Quick Response Code:



Department of Anesthesiology,
The Ohio State University Medical
Center, Columbus, Ohio,
¹Department of Anesthesia,
Critical Care and Pain Medicine,
Massachusetts General Hospital,
Boston, Massachusetts, USA

Address for correspondence:

Dr. Thomas J. Papadimos,
Department of Anesthesiology, The Ohio
State University Wexner Medical Center,
Columbus, Ohio, USA.
E-mail: Thomas.Papadimos@osumc.edu

consensus exists on the classification of bronchoscopic complications [Table 1].

Mechanical complications of fiberoptic bronchoscopy include oro- or nasopharyngeal, vocal cord, and airway trauma as well as bronchospasm, laryngospasm, pulmonary derecruitment/atelectasis, pneumothorax, airway hemorrhage, and introduction or exacerbation of infection. In general, the rates of mechanical complications have been, and continue to be, quite low. The most consistently reported mechanical complications are related to airway manipulation/trauma and bleeding.

A number of questionnaire-based, cross-sectional studies in the 1970s examined the reported rates of complications. A survey sent to 1,041 physicians who performed bronchoscopy reported 12 deaths in 48,000 cases, none of which were related to direct mechanical airway trauma and only two of which were associated with pneumonia (both cases of pneumonia preceded the bronchoscopy). Other mechanical complications included four brushes breaking off in the bronchi, at least one of which required thoracotomy, and 52 episodes of life-threatening airway complications (most commonly bronchospasm).^[8] Lindholm *et al.*, examined airway pressures of patients undergoing fiberoptic bronchoscopy and found that while spontaneously breathing patients had little change in airway pressures (average of - 5.2 cmH₂O during inhalation and + 3.5 cmH₂O during exhalation), intubated patients had a much wider range (as low as - 35 cmH₂O during inhalation and higher than + 35 cmH₂O during exhalation).^[11] This is most likely a combination of the small cross-sectional area remaining in the endotracheal tube, while a fiberoptic bronchoscope is in place, combined with dyssynchronous breathing from the

patient.^[11] The pattern of these pressure changes leads to a decrease in vital capacity (as tidal volume is restricted by high pressures and is lost via bronchoscopic suction), and a decrease in forced expiratory volume secondary to obstructed exhalation, which increases auto-positive end-expiratory pressure (PEEP) and functional residual capacity (FRC). This increase in auto-PEEP and FRC may actually protect against hypoxemia, particularly if the patient is breathing 100% oxygen, although following removal of the bronchoscope the PEEP and FRC will decrease, at this point atelectasis, bronchospasm, and laryngospasm may all lead to post-procedural hypoxemia unless treated promptly.^[12,13] Prolonged suctioning during bronchoscopy can lead to further derecruitment and atelectasis, as well as worsening of post-procedural hypoxemia.^[11,13] Despite these physiologic derangements, mechanical rates of pulmonary complications remain low with rates of pneumothorax from 0.07 to 0.16%, and respiratory failure from 0.2 to 0.31% in more recent studies.^[3,14] Rates of more minor pulmonary mechanical complications including bronchospasm and laryngospasm range from 0.26 to 2%.^[3,6,14]

The cross-sectional study from Suratt *et al.*, also called attention to the variability in cleaning practices of fiberoptic bronchoscopes ranging from water or saline only, to meat tenderizer, to alcohol,^[8] yet the rate of pneumonia (as reported) was remarkably low. This was confirmed by Credle *et al.*, who reported only two instances of pneumonia in 24,521 procedures.^[9] Kovaleva *et al.*, demonstrated that *Pseudomonas aeruginosa* is the most commonly transmitted organism by an improperly cleaned bronchoscope, most likely secondary to its ability to form biofilm in the bronchoscope channels.^[15] Infection can also be introduced from the oro- or nasopharynx into the lower respiratory tract (as well as from an infected to a non-infected area of the lung). Pharyngeal microbes are most common in this scenario: Streptococcus, Staphylococcus, Moraxella, Neisseria, and anaerobic bacteria.^[15] A prospective observational study of 13 hospitals confirmed a low reported rate of pneumonia as 0.6% (five of 908 procedures) in fiberoptic bronchoscopy.^[7] The expectation is that with modern, standard cleaning of bronchoscopes, and use of sterile technique where possible that these rates are even lower today.

Traditionally, bronchoscopic hemorrhage was thought to be frequently fatal and associated with large tumors.^[8] Dedicated prospective data did not identify any cases of hemorrhage requiring transfusion, but did report bleeding in 0.7% (six of 908) cases.^[8] Those with preexisting bleeding disorders were not overrepresented among those patients with bleeding complications; this suggests bleeding was likely mechanical and not coagulopathic.^[7] Hemorrhagic complications were significantly higher in patients who had transbronchial biopsies, a trend that has persisted over decades.^[3,5] Rates of bleeding were higher (2%) in a

Mechanical	Complication	
Trauma	Oropharyngeal	
		Nasopharyngeal
		Vocal cords
		Glottic structures
		Airway
	Bronchospasm	
	Laryngospasm	
	Atelectasis/derecruitment	
	Elevated airway pressures	
	Hemorrhage	
	Infection	
Systemic	Procedure-related	Vasovagal syncope
		Nausea/vomiting
		Aspiration
		Hypoxemia
		Hypercarbia
	Medication-related	Sedation
		Non-sedation medications
	Comorbid illness	Myocardial dysfunction/arrhythmia
		Pulmonary insufficiency
		Elevated intracranial pressure (ICP)
		Death

prospective analysis of 205 cases in a teaching hospital, which could be attributed to the majority of operators being trainees, higher rates of interventional procedures (biopsies), the specific patient population of the teaching hospital, or the use of more detailed outcome measurements (i. e., underreporting in prior studies).^[6] For example, hemorrhage was specifically quantified as > 40 mL within 15 min or > 200 mL within 24 h of the procedure.^[6]

Two decades later, a retrospective review demonstrated markedly lower rates of complications in a large academic medical center.^[3] Hemorrhage (>50 mL) occurred in only five (0.12%) out of 4,273 cases of fiberoptic bronchoscopy, with only one requiring intubation, and an unrelated single case (0.02%) of epistaxis.^[3] These results were confirmed in a Greek study in 2008 that demonstrated a rate of 0.17% of pulmonary hemorrhage (>50 mL).^[14]

Systemic complications are primarily related to the procedure itself, medication administration, or patient comorbidities. Systemic complications related to the procedure included vasovagal syncope, nausea/vomiting, aspiration, and hypoxemia. Complications related to medications can be anesthetic or sedation-related, as well as procedural-medication related (e. g., local anesthetics, glycopyrrolate). Finally, comorbidities including myocardial dysfunction, pulmonary insufficiency, or special cases such as increased ICP can predispose to unique complications.

Initial rates of systemic complications varied widely based on reporting. In 1978, Pereira *et al.*, reported a 2.4% incidence of vasovagal reaction, and 0.2% nausea and vomiting.^[7] These rates were significantly decreased by 1995 where Pue and Pacht demonstrated a 0.05% incidence of vasovagal syncope and 0.1% incidence of vomiting.^[3] Rates of aspiration are inconsistently reported across all studies likely reflecting the difficulty in making the diagnosis unless frank aspiration is observed. This class of complication is also likely intimately tied to the type and amount of sedation received by the patient. A cross-sectional study by Simpson *et al.*, demonstrated wide variability in sedation practices at that time.^[16] As early as the 1970s, cases of death related to both sedation and local anesthetics were reported surrounding fiberoptic bronchoscopy.^[8] Subsequently, no cases of sedation-related morbidity or local anesthetic toxicity were reported by Pue and Pacht in the 1995 study.^[3] They attributed their lower rate of complications to close monitoring (including pulse oximetry) and immediate availability of resuscitation equipment. It may be that standardization of sedation practices and the use of supplemental oxygenation also played a role in the decrease in sedation and anesthesia-related morbidity and mortality.^[16]

During the initial decade of fiberoptic bronchoscopy the major mortality burden was related to comorbid disease.

Myocardial infarction was associated with 33% of deaths, with another 17% related to preexisting pulmonary disease (pneumonia and emphysema) and another one of 12 patient deaths reported as being “in extremis” before the procedure.^[8] Additional morbidity was related to cardiac arrest from unspecified causes.^[8] It has been reported that heart rate, blood pressure, and cardiac output all increase during fiberoptic bronchoscopy, and that increases in myocardial oxygen demand may induce arrhythmias or ischemia in at-risk patients.^[13,17] Indeed unspecified cardiac arrest accounted for much of the reported mortality in early studies.^[6-8] Rates of ST changes during fiberoptic bronchoscopy have been reported as high as 17% (for patients over age 50),^[18] but severe arrhythmias are cited less than 0.1% of the time.^[19] More difficult to quantify is the effect of bronchoscopy on patients with preexisting pulmonary disease (often the indication for the procedure). Pulmonary-related deaths from fiberoptic bronchoscopy are almost always related to the intersection of underlying disease (large tumor and pneumonia) and the stress of the procedure itself.

Another area of concern frequently with ICU patients is intracranial pressure during fiberoptic bronchoscopy. Increased airway pressures may be transmitted to the thoracic space and therefore raise intracranial pressure (ICP) (raising both systolic blood pressure and impairing venous return). However, the data on high extrinsic PEEP does not reliably show an increase in ICP.^[20] A series of 26 fiberoptic bronchoscopies performed in patients with ICP monitors demonstrated an increase in ICP in 81% of cases, however the mean arterial pressure also increased leading to a normal cerebral perfusion pressure in all cases, and no cases had neurologic sequelae.^[21] It is therefore common practice not to withhold fiberoptic bronchoscopy in patients with elevated ICP when the procedure is indicated, but to use sedation and paralysis if necessary to attempt to mitigate the increase in ICP in unstable patients.

Complication rates from comorbid disease have fallen dramatically over time, which is likely attributable to improved monitoring and early intervention, as well as patient selection.^[3] Furthermore, the incidence of complications is similar for patients in the bronchoscopy suite and the intensive care unit, indicating that fiberoptic bronchoscopy can be performed safely even in the sickest patients regardless of location.^[3,10] However, it is important to note that the rate of minor complications such as hypoxemia and nonmalignant arrhythmia is significantly higher in the ICU population, so vigilance is paramount.^[13,19,22]

Nonetheless, flexible bronchoscopy has improved its capabilities by introducing enhancements that not only help in diagnosing malignancies, but also identifying areas of premalignancy [Figure 1].^[2] These improvements

include endobronchial ultrasound, electromagnetic navigation, autofluorescence bronchoscopy, narrow-band imaging, and confocal fluorescence microscopy. Additionally, it has been used to support placement of percutaneous dilational tracheostomy.^[23] It is a support adjunct to help guide the site of tracheal puncture entry of the tracheostomy, and to avoid damage to the posterior wall of the trachea.^[24,25] However, this function of fiberoptic bronchoscopy is being challenged by the use of ultrasound.^[26] Advances in equipment, monitoring techniques, and anesthetic medications continue to improve the margin of safety and make this procedure widely applicable.

Rigid bronchoscopy

The technique of rigid bronchoscopy was pioneered by Gustav Killian in 1876 when he used an esophagoscope to remove a pork bone from a patient’s airway, thus preventing a tracheostomy.^[27] The rigid bronchoscope was improved upon by Chevalier Jackson in the early 20th century.^[28] Though the invention of the flexible fiberoptic bronchoscope by Ikeda in 1967 changed the field of bronchoscopy, the use of the rigid bronchoscope remains an important technique in the management of upper airway disease.^[28,29]

In adults, the primary indications for using the rigid scope are central airway obstruction secondary to neoplastic and nonneoplastic pathologies, massive hemoptysis, mucus plugging, and blood clot removal, as well as foreign bodies.^[30,31] There has been an expanding interest in the management of central airway obstruction by pulmonologists and this has led to a renewed interest in rigid bronchoscopy.^[32] More than just treating cancer-related central airway obstruction mechanically, rigid bronchoscopy also makes possible a number of therapies such as laser/photoresection, endobronchial stents, balloon dilation, electrocautery, use of the argon beam, and cryotherapy.^[1] The wide channel of the rigid bronchoscope lends itself to easier removal of foreign bodies from the airway and debulking of masses, easier control of hemorrhage during therapeutic interventions in the trachea and mainstem bronchi, as well as easier dilation of proximal airways, and easier deployment of stents and other airway implantables, all while allowing for relative ease of ventilation.^[29,33] Despite the multitude of indications and procedures: Sex, age, and the aim of the procedure are not associated with complications.^[29]

Unlike fiberoptic bronchoscopy, rigid bronchoscopy is performed in the operating room under general anesthesia. Performing rigid bronchoscopy under general anesthesia adds the potential complication of proceduralist and anesthesiologist sharing the airway but also adds a degree of safety by allowing the proceduralist to focus on airway intervention, while the anesthesiologist prevents and manages mechanical

and systemic complications as they arise.^[29,34] Here the anesthesiologists, with the bronchoscope operator, need to navigate the multiple approaches to airway management, such as apneic oxygenation, spontaneous ventilation (assisted or otherwise), controlled mechanical ventilation, high frequency, and manual jet ventilation.^[32] Relative contraindications to rigid bronchoscopy include uncontrolled coagulopathy, oxygenation, and ventilator demands that are at the clinical extremes, especially in the hands of an inexperienced operator.^[35] The type and rate of complications of rigid bronchoscopy are similar to those of flexible fiberoptic bronchoscopy and can likewise be divided into mechanical and systemic complications. Complications in either category can potentially result in death [Table 2].

The most common mechanical complications of rigid bronchoscopy are trauma to the teeth, oropharynx, vocal cords or other glottic structures, laryngospasm, pneumothorax, and hemorrhage, and death.^[29,30,36-38] Systemic complications include vasovagal syncope,

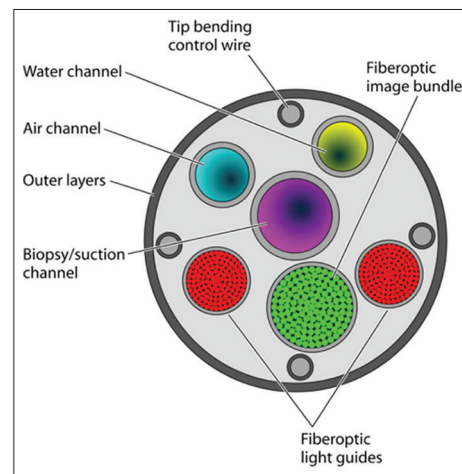


Figure 1: Schematic diagram of flexible bronchoscope design demonstrating multiple changes that lend to its efficiency and value to the operator (Source: Kovaleva et al.)

Table 2: Complications of rigid bronchoscopy		
Mechanical	Complication	
	Trauma	Teeth
		Oropharynx Vocal cords Glottic structures Airway
	Bronchospasm Laryngospasm Atelectasis/decreitment Hemorrhage	
Systemic	Procedure-related	Vasovagal syncope Aspiration Hypoxemia Hypercarbia
	Medication-related Comorbid illness	General anesthesia Myocardial dysfunction/arrhythmia Post-procedural respiratory failure Death

hypoxemia, hypercarbia, medication effects of general anesthesia, arrhythmia, post-procedural respiratory failure, and death.^[29,30,32,36-40]

It should be noted that there are relatively few prospective studies providing quantifiable complication rates during and after rigid bronchoscopy, so the true rate of complications resulting from the procedure is difficult to pinpoint and will vary by operator experience and institution. However, advances in equipment, monitoring, and anesthetic drugs have increased the overall margin of safety for rigid bronchoscopy. One retrospective study reviewed 775 cases of rigid bronchoscopy in a university hospital between 1992 and 1999 and found that 86.7% of cases occurred without any of the above listed complications.^[29] In this study 103/775 (13.3%) of cases had complications, which included bleeding (6.6%), respiratory failure (5.3%), cough (0.6%), death (0.4%), and arrhythmia (0.3%). A lesion at or near the carina had the highest correlation with procedural complications.^[29] Furthermore, rigid bronchoscopy seems to be safe to use in neurosurgery patients with space-occupying lesions.^[39]

Comparison of complications of flexible as compared to rigid bronchoscopy.

Another notable retrospective study compared the complication rate of flexible fiberoptic bronchoscopy under topical anesthesia with the complication rate of rigid bronchoscopy under general anesthesia.^[36] Lukomsky *et al.*, reviewed 3,449 rigid bronchoscopy procedures and complications associated with rigid bronchoscopy occurred in 173 of 3,449 cases (5%); four rigid bronchoscope cases were complicated by pneumothorax [Figure 2] and six cases were complicated by death (four due to hypoxia) resulting in a fatality rate of 0.17%.^[36]

One underreported complication during rigid bronchoscopy with laser is airway fire [Figure 3]. With advances in technology, laser can now be used

through flexible fiberoptic bronchoscopes, rigid bronchoscopes, during esophagoscopy, and during suspension microlaryngoscopy. Due to this variety of applications, most reports of the incidence of airway fire are not specific to rigid bronchoscopy. In order to ensure the highest margin of safety in preventing airway fire, good communication must exist between the anesthesiologist and proceduralist, and the concentration of inhaled oxygen when the laser is in use should be < 40%.^[33] Standard precautions should be adhered to during laser airway procedures, especially when flammable objects (stents and endotracheal tubes) are also present in the airway.

As Dutau *et al.*, have summarized; (i) rigid bronchoscopy is preferred clinical tool for the majority of therapeutic pulmonary interventions, (ii) this tool has a dual use in that it can be used for visualization of pathology/tumors and for interventions, (iii) extensive training is needed before it can be deployed by a practitioner, (iv) it is mandatory for use in stenting of the airway and with the use of silicone stents (being reasonably minimally invasive), (v) “can occasionally represent a bridge to definitive surgical management”, and (vi) when surgery is not possible due to a patient’s condition, rigid bronchoscopy can be used for palliative interventions.^[31]

The rigid bronchoscope has had several new innovations that enhance patient safety and better facilitate its use for the practitioner.^[2] For example, the Bryan–Dumon II rigid bronchoscope has an operator head with a universal instrumentation barrel. The operator head can be used on any Dumon series color-coded tracheal and bronchial scope (on the proximal end of the scope). The Texas Rigid Integrated (by Wolff) bronchoscope enables the operator to access a larger working area without visual interruption with the availability of separate channels for instruments and optics. While oxygen saturation is fairly easy to maintain with larger bronchoscopes, monitoring FiO_2 , minute ventilation, and airway pressures remain

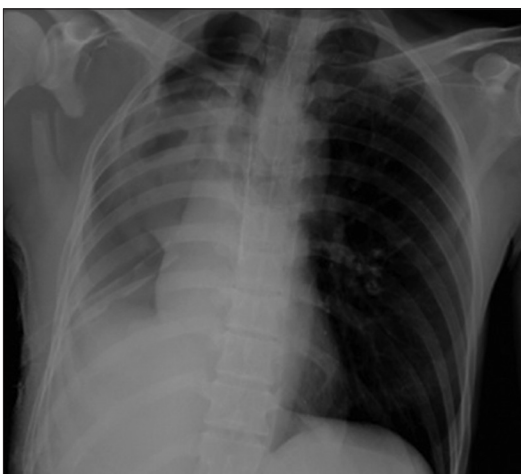

Figure 2: Post-bronchoscopy pneumothorax (R) (Source: Author file; TJP)

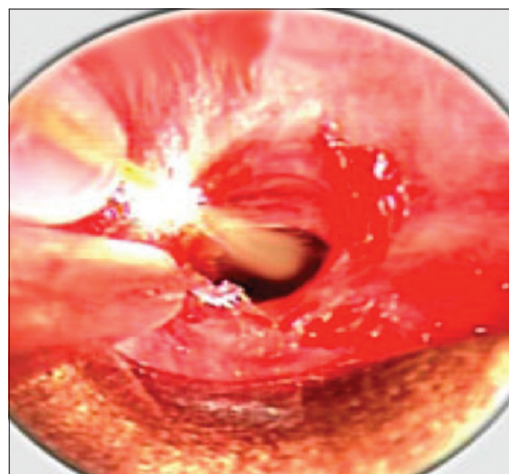


Figure 3: Sparking that may lead to airway fire (Source: Google images)

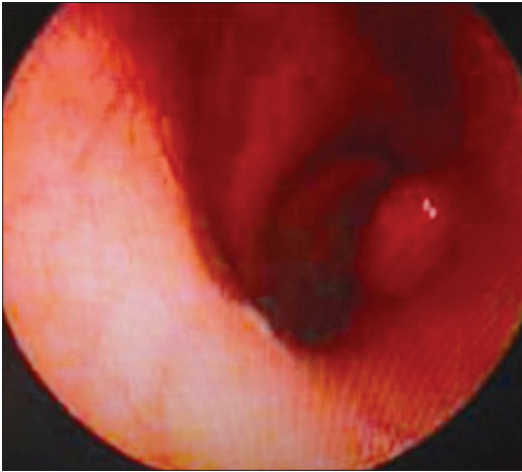


Figure 4: Bleeding airway after biopsy (Source: Google images)

difficult to monitor, which can lead to hyperinflation and pneumothorax.^[37] The Herner bronchoscope (by Wolff) has a sampling/measuring port that allows monitoring of carbon dioxide, oxygen, and airway pressures. The expectation exists that technologic innovation will continue to improve the safety and efficacy of the rigid bronchoscope.

The bronchoscopically-induced bleeding patient

Although infrequent, bronchoscopically-induced bleeding needs special mention [Figure 4]. It is a frequently encountered problem, and usually abates on its own. The skilled and mature operator has fewer complications than novices, nonetheless, it is very safe even in the hands of trainees.^[38] However, the operator needs to be cognizant of methods to attenuate any bleeding complications. At the time of hemorrhage the nonbleeding lung must be protected. Whether the patient is intubated or not, the patient should be positioned with the bleeding lung in the decubitus, dependent position (if hemodynamics permit), and if necessary, a double lumen tube will have to be placed in the nonbleeding lung (this will require special skills).^[41] Other methods of bleeding control include the instillation of cooled saline into the bronchus and then clamping the bronchus with the fiberoptic scope tip.^[42] If this does not work then 5 mL of thrombin may be instilled (5,000 U dissolve in saline),^[43] or, alternately, 2 mL of 1:1,000 epinephrine mixed with normal saline in a 1:10 mixture in order to produce vasoconstriction, thereby reducing bleeding (no more than three 2-mL aliquots are recommended).^[41] There has also been use of tranexamic acid with significant airway bleeding,^[44,45] and even activated factor VII has been instilled into the lungs with successful resolution of bleeding (author TJP, case to be published). Sometimes there are large thrombi that can block the airways once the bleeding stops, and these may need to be removed with cryotherapy, which has been in use for over 30 years [Figure 5].^[46] It is also important during an episode of bleeding to

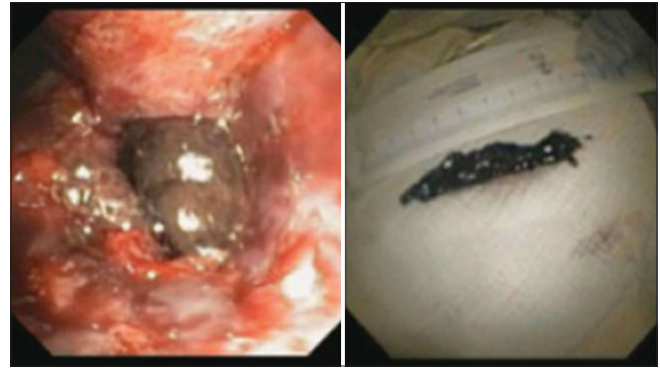


Figure 5: Clot in bronchus that has been subjected to cryotherapy and removed (Source: Author file; TJP)

have good visualization of the airways and the source of bleeding. Usually the scope's removal for manual cleaning to visualize the field is rarely needed, and only is necessary in the face of massive hemorrhage.^[41] In less than dire circumstances, the scope tip can be cleaned by gently rubbing it vertically against the mucosa of the cartilaginous part of the tracheal wall.^[41] If this maneuver does not clear the operator's vision, then place the scope as described above against the tracheal wall and flush the operating port vigorously.^[41]

CONCLUSION

The majority of complications, as expected, occur in patients with high levels of comorbid disease undergoing more extensive therapeutic interventions. Bronchoscopy requires skilled operators and continues to evolve technologically to the advantage of both the physician and the patient. Overall, both rigid and flexible bronchoscopy, are safe and effective procedures for diagnosis and treatment of airway and pulmonary pathology.

Financial support and sponsorship

Nil.

Conflicts of interest

There are no conflicts of interest.

REFERENCES

1. Ayers ML, Beamis JF Jr. Rigid bronchoscopy in the twenty-first century. *Clin Chest Med* 2001;22:355-64.
2. Yarmus L, Feller-Kopman D. Bronchoscopes of the twenty-first century. *Clin Chest Med* 2010;31:19-27.
3. Pue CA, Pacht ER. Complications of fiberoptic bronchoscopy at a university hospital. *Chest* 1995;107:430-2.
4. Fazlalizadeh H, Adimi P, Kiani A, Malekmohammad M, Jabardarjani HR, Soltaninejad F, et al. Evaluation of bronchoscopy complications in a tertiary health care center. *Tanaffos* 2014;13:48-50.
5. Burgher LW. Complications and results of transbronchoscopic lung biopsy. *Nebr Med J* 1979;64:247-8.

6. Dreisin RB, ALbert PK, Talley PA, Kryger MH, Scoggin CH, Zwillich CW. Flexible fiberoptic bronchoscopy in the teaching hospital. Yield and complications. *Chest* 1978;74:144-9.
7. Pereira W Jr, Kovnat DM, Snider GL. A prospective cooperative study of complications following flexible fiberoptic bronchoscopy. *Chest* 1978;73:813-6.
8. Suratt PM, Smiddy JF, Gruber B. Deaths and complications associated with fiberoptic bronchoscopy. *Chest* 1976;69:747-51.
9. Credle WF Jr, Smiddy JF, Elliott RC. Complications of fiberoptic bronchoscopy. *Am Rev Respir Dis* 1974;109:67-72.
10. Turner JS, Wilcox PA, Hayhurst MD, Potgieter PD. Fiberoptic bronchoscopy in the intensive care unit--a prospective study of 147 procedures in 107 patients. *Crit Care Med* 1994;22:259-64.
11. Lindholm CE, Ollman B, Snyder JV, Millen EG, Grenvik A. Cardiorespiratory effects of flexible fiberoptic bronchoscopy in critically ill patients. *Chest* 1978;74:362-8.
12. Matsushima Y, Jones RL, King EG, Moysa G, Alton JD. Alterations in pulmonary mechanics and gas exchange during routine fiberoptic bronchoscopy. *Chest* 1984;86:184-8.
13. Kreider ME, Lipson DA. Bronchoscopy for atelectasis in the ICU: A case report and review of the literature. *Chest* 2003;124:344-50.
14. Kaparianos A, Argyropoulou E, Sampsonas F, Zania A, Efremidis G, Tsiamita M, et al. Indications, results and complications of flexible fiberoptic bronchoscopy: A 5-year experience in a referral population in Greece. *Eur Rev Med Pharmacol Sci* 2008;12:355-63.
15. Kovaleva J, Peters FT, van der Mei HC, Degener JE. Transmission of infection by flexible gastrointestinal endoscopy and bronchoscopy. *Clin Microbiol Rev* 2013;26:231-54.
16. Simpson FG, Arnold AG, Purvis A, Belfield PW, Muers MF, Cooke NG. Postal survey of bronchoscopic practice by physicians in the United Kingdom. *Thorax* 1986;41:311-7.
17. Trouillet JL, Guiguet M, Gibert C, Fagon JY, Dreyfuss D, Blanchet F, et al. Fiberoptic bronchoscopy in ventilated patients. Evaluation of cardiopulmonary risk under midazolam sedation. *Chest* 1990;97:927-33.
18. Matot I, Kramer MR, Glantz L, Drenger B, Cotev S. Myocardial ischemia in sedated patients undergoing fiberoptic bronchoscopy. *Chest* 1997;112:1454-8.
19. Jin F, Mu D, Chu D, Fu E, Xie Y, Liu T. Severe complications of bronchoscopy. *Respiration* 2008;76:429-33.
20. Stahl, DL, North CM, Lewis A, Kimberly WT, Hess DR. Case scenario: Power of positive end-expiratory pressure: Use of esophageal manometry to illustrate pulmonary physiology in an obese patient. *Anesthesiology* 2014;121:1320-6.
21. Kerwin AJ, Croce MA, Timmons SD, Maxwell RA, Malhotra AK, Fabian TC. Effects of fiberoptic bronchoscopy on intracranial pressure in patients with brain injury: A prospective clinical study. *J Trauma* 2000;48:878-82.
22. Wang KP, Mehta AC, Turner FJ, editors. *Flexible Bronchoscopy*. 3rd Edition. Oxford: Wiley-Blackwell; 2012.
23. Freeman BD, Morris PE. Tracheostomy practice in adults with acute respiratory failure. *Crit Care Med* 2012;40:2890-6.
24. Hinerman R, Alvarez F, Keller CA. Outcome of bedside percutaneous tracheostomy with bronchoscopic guidance. *Intensive Care Med* 2000;26:1850-6.
25. Fernandez, L, Norwood S, Roettger R, Gass D, Wilkins H 3rd. Bedside percutaneous tracheostomy with bronchoscopic guidance in critically ill patients. *Arch Surg* 1996;131:129-32.
26. Gobatto AL, Besen BA, Tierno PF, Mendes PV, Cadamuro F, Joelsons D, et al. Comparison between ultrasound- and bronchoscopy-guided percutaneous dilational tracheostomy in critically ill patients: A retrospective cohort study. *J Crit Care* 2015;30:220.e13-7.
27. Kollofrath O. Removal of a bone stuck in the right bronchus using direct laryngoscopy. *MMW* 1897;38:1038-9.
28. Panchabhai TS, Mehta AC. Historical perspectives of bronchoscopy. Connecting the dots. *Ann Am Thorac Soc* 2015;12:631-41.
29. Drummond M, Magalhaes A, Hespagnol V, Marques A. Rigid bronchoscopy: Complications in a university hospital. *J Bronchol* 2003;10:177-81.
30. Petrella F, Borri A, Casiraghi M, Cavaliere S, Donghi S, Galetta D, et al. Operative rigid bronchoscopy: Indications, basic techniques and results. *Multimed Man Cardiothorac Surg* 2014;2014.
31. Dutau H, Vandemoortele T, Breen DP. Rigid bronchoscopy. *Clin Chest Med* 2013;34:427-35.
32. Pathak V, Welsby I, Mahmood K, Wahidi M, MacIntyre N, Shofer S. Ventilation and anesthetic approaches for rigid bronchoscopy. *Ann Am Thorac Soc* 2014;11:628-34.
33. Goudra BG, Singh PM, Borle A, Farid N, Harris K. Anesthesia for advanced bronchoscopic procedures: State-of-the-art review. *Lung* 2015.
34. Dincq AS, Gourdin M, Collard E, Ocak S, D'Odemont JP, Dahlqvist C, et al. Anesthesia for adult rigid bronchoscopy. *Acta Anaesthesiol Belg* 2014;65:95-103.
35. Nicastrì DG, Weiser TS. Rigid bronchoscopy: Indications and techniques. *Oper Tech Thorac Cardiovasc Surg* 2012;17:44-51.
36. Lukomsky GI, Ovchinnikov AA, Bilal A. Complications of bronchoscopy: Comparison of rigid bronchoscopy under general anesthesia and flexible fiberoptic bronchoscopy under topical anesthesia. *Chest* 1981;79:316-21.
37. Hasdiraz L, Oguzkaya F, Bilgin M, Bicer C. Complications of bronchoscopy for foreign body removal: Experience in 1,035 cases. *Ann Saudi Med* 2006;26:283-7.
38. Facciolongo N, Patelli M, Gasparini S, Lazzari Agli L, Salio M, Somonassi C, et al. Incidence of complications in bronchoscopy. Multicentre prospective study of 20,986 bronchoscopies. *Monaldi Arch Chest Dis* 2009;71:8-14.
39. Grosu HB, Morice RC, Sarkiss M, Bashoura L, Eapen GA, Jimenez CA, et al. Safety of flexible bronchoscopy, rigid bronchoscopy, and endobronchial ultrasound-guided transbronchial needle aspiration in patients with malignant space-occupying brain lesions. *Chest* 2015;147:1621-8.
40. Tomaske M, Gerber AC, Weiss M. Anesthesia and periinterventional morbidity of rigid bronchoscopy for tracheobronchial foreign body diagnosis and removal. *Paediatr Anaesth* 2006;16:123-9.
41. Cordasco EM Jr, Mehta AC, Ahmad M. Bronchoscopically induced bleeding. A summary of nine years' Cleveland clinic experience and review of the literature. *Chest* 1991;100:1141-7.
42. Kitamura S, Wagai F. Local administration of cold saline for the treatment of bleeding induced by transbronchial biopsy. *J Jpn Soc Bronchol* 1984;6:309.
43. Kitamura S. Local administration of thrombin solution for the treatment of intrabronchial bleeding. *Internal Med (Tokyo)* 1984;53:747.
44. Solomonov A, Fruchter O, Suckerman T, Brenner B, Yigla M. Pulmonary hemorrhage: A novel mode of therapy. *Respir Med* 2009;103:1196-200.
45. Zamani A. Bronchoscopic intratumoral injection of tranexamic acid to prevent excessive bleeding during multiple forceps biopsies of lesions with a high risk of bleeding: A prospective case series. *BMC Cancer* 2014;14:143.
46. Sanderson DR, Neel HB 3rd, Fontana RS. Bronchoscopic cryotherapy. *Ann Otol Rhinol Laryngol* 1981;90:354-8.