



## Case Report

## Epicardially placed implantable cardioverter-defibrillator for a child with congenital long QT syndrome

Hirotaro Sugiyama, MD, Motomi Tachibana, MD\*, Hiroshi Morita, MD, Nobuhiro Nishii, MD, Akihito Miyoshi, MD, Hiroyasu Sugiyama, MD, Koji Nakagawa, MD, Atsuyuki Watanabe, MD, Kazufumi Nakamura, MD, Hiroshi Ito, MD

Department of Cardiology, Okayama University Hospital, 2-5-1 Shikata-cho, Kita-ku, Okayama 700-8558, Japan

## ARTICLE INFO

## Article history:

Received 17 September 2016

Received in revised form

7 October 2016

Accepted 18 October 2016

Available online 10 November 2016

## Keywords:

Implantable cardioverter-defibrillator  
Congenital long QT syndrome

## ABSTRACT

A 7-year-old boy presented at our hospital with syncope. At birth, electrocardiography had shown a long QT interval with torsade de pointes (TdP). Congenital long QT syndrome (LQTS) had been diagnosed by genetic testing, and was successfully controlled with oral propranolol. At age 7, TdP had recurred with syncope. Electrocardiography revealed a prominent long QT interval with T-wave alternans. The propranolol dose was increased, but TdP remained uncontrolled. A cardioverter-defibrillator (ICD) was implanted epicardially, and TdP completely resolved with atrial pacing. We report this rare case of ICD implantation in a child with LQTS.

© 2016 Japanese Heart Rhythm Society. Published by Elsevier B.V. This is an open access article under the CC BY-NC-ND license (<http://creativecommons.org/licenses/by-nc-nd/4.0/>).

### 1. Introduction

An implantable cardioverter-defibrillator (ICD) effectively prevents sudden cardiac death. However, methods for ICD implantation in children have not been established [1,2]. Here, we present the case of a pediatric patient with a successfully implanted ICD using an epicardial lead system.

### 2. Case report

A 7-year-old boy was referred to our hospital for syncope. At birth, electrocardiography had shown a long QT interval with frequently recurrent torsade de pointes (TdP). He had been diagnosed with type 2 congenital long QT syndrome (LQTS) by genetic testing (*KCNH2* mutation). Initiation of propranolol treatment resulted in the disappearance of TdP. At age 7, TdP recurred with syncope.

On admission to our hospital, electrocardiography revealed normal sinus rhythm with a heart rate of 61 beats/min, prolongation of the QT interval to 566 ms, and T-wave alternans (Fig. 1a). TdP was frequently seen, with and without symptoms (Fig. 1b). We attempted to increase the dose of propranolol gradually to 30 mg/day, but TdP remained uncontrolled. Sinus

bradycardia and malaise appeared and were exacerbated by propranolol, preventing further increases in dose. We therefore decided to attempt ICD implantation. As an ordinary intravenous lead system was unsuitable for his small body, chest surgery was performed to place the ICD epicardially (Fig. 2a–c). The atrial lead (4968; Medtronic, Minneapolis, MN, USA) was placed on the epicardium of the free wall of the right atrium, the ventricular lead (4968; Medtronic) was fixed to the epicardium of the *anterior horn* and inferior wall of the right ventricle, and the shock lead (6944; Medtronic Inc.) was implanted in the transverse sinus of the heart with the tip placed between the sinus vena cava and aorta. The generator was implanted in the abdomen, under the rectus abdominis muscle (Evera XT; Medtronic). The thresholds of pacing, sensing, and impedance of the leads were satisfactory.

Postoperatively, we increased the dose of propranolol to 45 mg/day. Atrial pacing and ventricular sensing to 80 beats/min were observed all day. TdP and T-wave alternans disappeared with a shorter QT interval (Fig. 1c). Remote monitoring of the device revealed no recurrence of TdP or ICD shock.

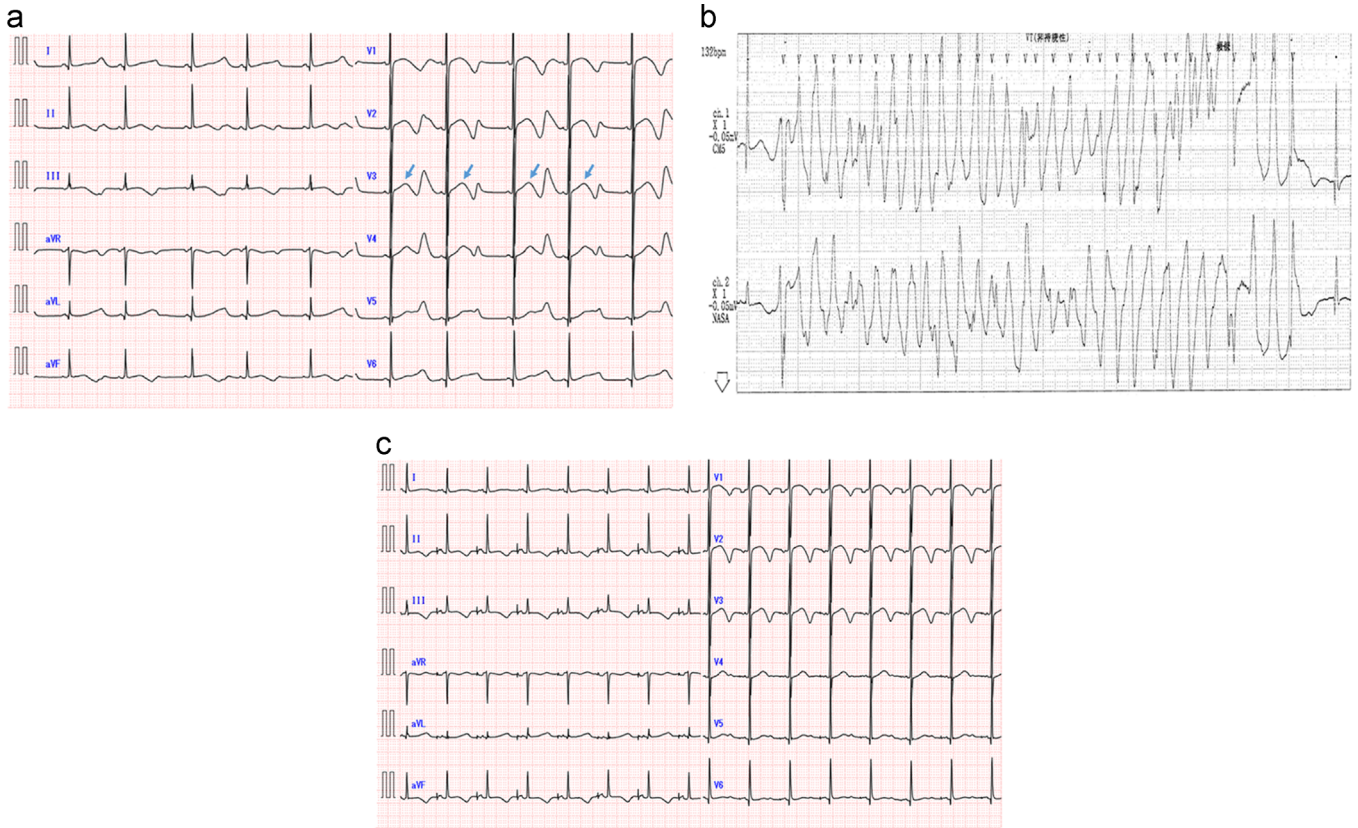
### 3. Discussion

In this case, as the patient was not considered able to tolerate further increases in the dose of  $\beta$ -blocker, we considered ICD implantation for secondary prevention [1]. During 12 months of postoperative follow-up, lethal arrhythmia was not observed. This result was attributable to a sufficient dose of propranolol, which decreased the sympathetic tone. Sinus bradycardia frequently does

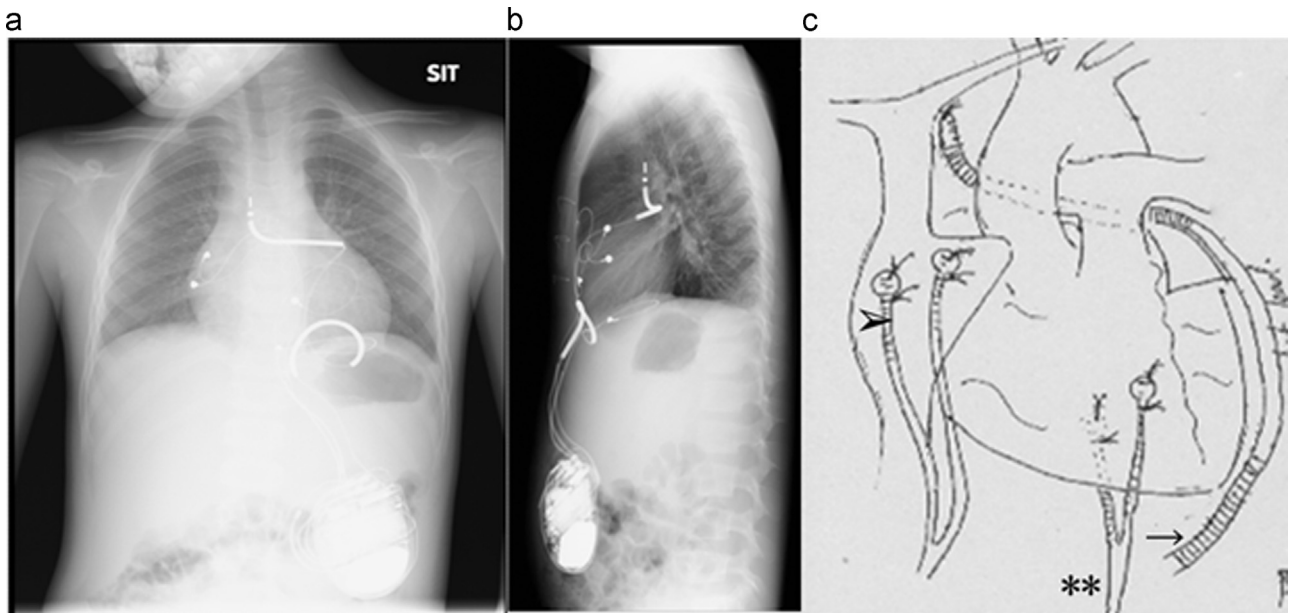
Abbreviations: ICD, implantable cardioverter-defibrillator; LQTS, long QT syndrome; TdP, torsade de pointes

\* Corresponding author. Fax: +81 86 235 7353.

E-mail address: [motomitachibana@yahoo.co.jp](mailto:motomitachibana@yahoo.co.jp) (M. Tachibana).



**Fig. 1.** (a) Electrocardiography on admission shows long QT interval (566 ms) and T-wave alternans (arrow). (b) The Holter electrocardiogram shows torsade de pointes. (c) Electrocardiography 3 months after ICD implantation. T-wave alternans disappeared. ICD, implantable cardioverter-defibrillator.



**Fig. 2.** (a) Postoperative chest radiogram, frontal view. (b) Postoperative chest radiogram, lateral view. (c) Schema of the operation, showing atrial lead (arrowhead), ventricular lead (\*\*), and shock lead (arrow).

not allow increases in the dose of  $\beta$ -blocker, while cardiac pacing in our patient prevented bradycardia. The stable RR interval provided by pacing was another effective factor. Instability in the RR interval causes fluctuations in the QT interval, inducing TdP. The combination of  $\beta$ -blocker administration and cardiac pacing may thus be quite effective for patients with LQTS.

Only 1% of ICD implantations are performed in children. As a result, established methods of pediatric ICD implantation are lacking, and long-term outcomes are still unclear. Non-transvenous ICD systems are required in children [1,2], and we chose an epicardial system for our case. The advantage of this system is that the defibrillation threshold is lower than that with a

subcutaneous system, and cardiac strangulation caused by the leads is less likely than with a pericardial system [2]. Because the heart was sandwiched between the transverse sinus and the can located in the abdomen, we expected a lower defibrillation threshold. Survival of non-transvenous ICD systems is significantly shorter than that of transvenous systems because of complications [3]. Bryant et al. reported that the shock lead should not cover more than 40% of the surrounding heart to avoid cardiac strangulation [4]. Although cardiac pacing and  $\beta$ -blocker use effectively treated TdP in our patient, a defibrillator was still warranted to prevent lethal cardiac events, considering his long life expectancy.

#### 4. Conclusion

ICD implantation in children can be effective for secondary prevention of lethal arrhythmia.

#### Conflicts of interest

All authors declare no conflict of interest related to this study.

#### References

- [1] Spazzolini C, Mullally J, Moss AJ, et al. Clinical implications for patients with long QT syndrome who experience a cardiac event during infancy. *J Am Coll Cardiol* 2009;54:832–7.
- [2] Suzuki S, Motohashi S, Matsumoto M, et al. Surgical techniques for implanting implantable cardioverter defibrillators in children and infants. *Surg Today* 2014;44:1801–6.
- [3] Radbill AE, Friedman JK, Beul CI, et al. System survival of nontransvenous implantable cardioverter-defibrillators compared to transvenous implantable cardioverter-defibrillators in pediatric and congenital heart disease patients. *Heart Rhythm* 2010;7:193–8.
- [4] Bryant 3rd R, Aboutaleb A, Kim JJ, et al. Epicardial implantable cardioverter-defibrillator system placed in a 4.9-kg infant. *Tex Heart Inst J* 2011;38:421–3.