

Mediastinoscopic Bilateral Bronchial Release for Long Segmental Resection and Anastomosis of the Trachea

Jeong-Han Kang, M.D.*, In Kyu Park, M.D., Ph.D.***, Mi-Kyung Bae, M.D.***, Yoohwa Hwang, M.D.***

The extent of resection and release of the trachea is important for successful anastomosis. Bilateral bronchial dissection is one of the release techniques for resection of the lower trachea. We present the experience of cervical video-assisted mediastinoscopic bilateral bronchial release for long segmental resection and anastomosis of the lower trachea.

Key words: 1. Tracheal surgery
2. Mediastinoscopy

CASE REPORT

A 52-year-old man was referred for a tracheal mass. He had dyspnea for the past 10 months. The dyspnea had become aggravated 2 weeks earlier, and blood-tinged sputum developed simultaneously. Computed tomography revealed about a 4.5-cm mid-tracheal mass obstructing 80% of the tracheal lumen (Fig. 1). Infiltration to the adjacent tissue was suspected. However, there was no enlarged regional lymph node. The mass showed mild FDG uptake on positron emission tomography. On fiber-optic bronchoscopy, a protruding mass with an irregular surface was found at the mid-trachea. The mass was hypervascular and fragile. A biopsy was omitted due to the risk of bleeding and respiratory insufficiency. The clinical impression was adenoid cystic carcinoma of the trachea. In the operating room, an endotracheal tube was positioned proximally to the mass through the nasopharyngeal route by a bronchoscopic guide in deep sedation status with

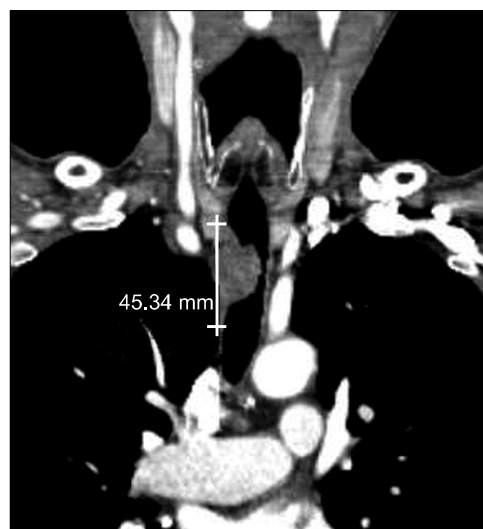

Fig. 1. A tracheal mass of about 4.5 cm length was observed at the mid-trachea by computed tomography.

**Department of Chest Surgery, Heymin General Hospital

***Department of Thoracic and Cardiovascular Surgery, Seoul National University Hospital, Seoul National University College of Medicine

***Department of Thoracic and Cardiovascular Surgery, Yonsei University College of Medicine

Received: September 14, 2010, Revised: March 20, 2011, Accepted: May 10, 2011

Corresponding author: In Kyu Park, Department of Thoracic and Cardiovascular Surgery, Seoul National University Hospital, Seoul National University College of Medicine, 101, Daehak-ro, Jongno-gu, Seoul 110-744, Korea
(Tel) 82-2-2072-2342 (Fax) 82-2-764-3664 (E-mail) ikpark@snu.ac.kr

© The Korean Society for Thoracic and Cardiovascular Surgery. 2011. All rights reserved.

© This is an open access article distributed under the terms of the Creative Commons Attribution Non-Commercial License (<http://creativecommons.org/licenses/by-nc/3.0>) which permits unrestricted non-commercial use, distribution, and reproduction in any medium, provided the original work is properly cited.

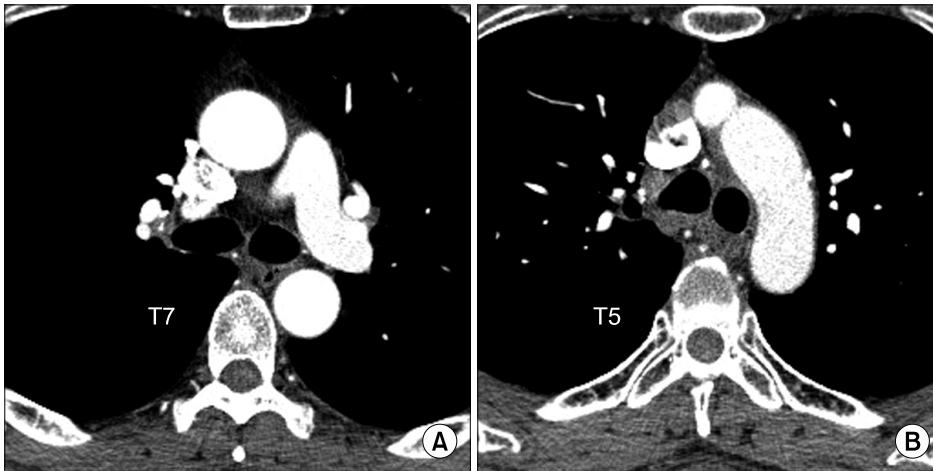


Fig. 2. Computed tomography after 12 months revealed an elevation of the carina by about 3 cm. (A) The carina was at the level of the upper margin of the T7 vertebra pre-operatively. (B) The carina was elevated to the level of the middle of the T5 vertebra after operation.

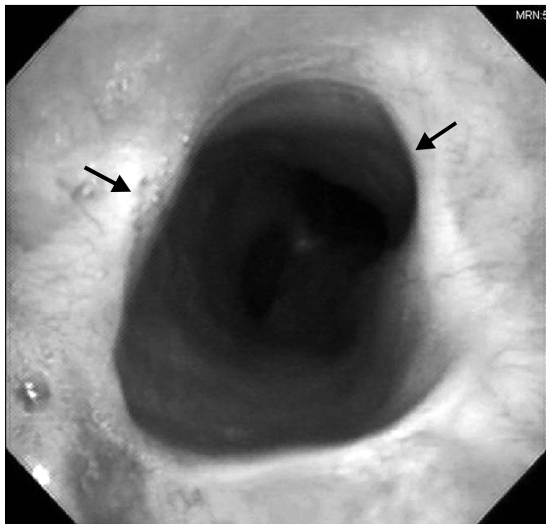


Fig. 3. Fiber-optic bronchoscopy after 12 months revealed mild anastomotic stenosis (arrow) at the cranial portion 5 cm from the carina.

spontaneous breathing. The neck was hyper-extended, and a collar incision was made after local anesthesia. The trachea was exposed and the distal margin of the mass was confirmed by bronchoscopy. After initiation of general anesthesia, the trachea was opened beyond the distal margin of the mass and another armored endotracheal tube was inserted to the distal trachea for mechanical ventilation. We found an irregularly shaped mass originating from the right posterior membranous wall. However, the longitudinal mucosal extension was much longer than expected, especially at the right posterolateral wall. To achieve complete resection and

preserve the trachea as much as possible, the trachea was resected obliquely at both ends. The longest length of the resected tracheal segment was 6.5 cm at the right posterolateral wall and the shortest length was 5.0 cm at the left anterolateral wall. In order to approximate both ends of trachea and minimize the tension of anastomosis, a proximal tracheal release was performed on the cricoid cartilage, and bilateral main bronchial release was performed under video-assisted mediastinoscopy (VAM). After dissection of the anterior and posterior wall of the trachea to the carina under direct vision, the anterior and posterior walls of both main bronchi were dissected under VAM. The bronchi were released to the proximal part of the intermediate bronchus on the right and to the origin of the upper lobe bronchus on the left. The subcarinal lymph nodes were sampled. Both bronchial arteries were preserved. End-to-end anastomosis was performed by rotating the distal end 90 degrees counter-clockwise and the proximal end 90 degrees clockwise. The pathologic diagnosis was adenoid cystic carcinoma. Both resection margins were clear. The mass had infiltrated into the paratracheal fibroadipose tissues. Cervical flexion was maintained for 10 days. Fiberoptic bronchoscopy on the 8th day revealed intact anastomosis. Computed tomography taken 12 months later revealed an approximately 3-cm elevation of the carina (Fig. 2). Fiber-optic bronchoscopy revealed mild anastomotic stenosis at the cranial portion 5 cm from the carina (Fig. 3). Postoperative radiotherapy was performed because of the close radial margin. The patient has been disease-free for 18 months.

DISCUSSION

Anatomic studies have attempted to answer the surgical questions of how much of the trachea could be resected for safe anastomosis. Mulliken and Grillo reported that cervico-mediastinal mobilization permitted removal of 4.5 cm (about seven rings) under 1,000 g tension, with cervical flexion, and intrathoracic right hilar dissection permitted removal of an additional 1.4 cm [1]. Maeda and Grillo found that transthoracic hilar dissection and division of the pulmonary ligament, with the cervical spine in the neutral position, permitted removal of 3 cm, intrapericardial dissection an additional 0.9 cm, and division of the left main bronchus with reimplantation to the bronchus intermedius an additional 2.7 cm [2]. Watanabe described a tracheal release technique through L-shaped unilateral mini-sternotomy with collar incision. He mobilized the trachea by dissecting it from the anterior sheath of the trachea through the carina to the bilateral main bronchi [3]. We concluded that bilateral main bronchial release can be performed by VAM without a sternotomy because cervical VAM is a frequently used procedure for the diagnosis and treatment of thoracic disease [4]. Suprahyoid release is a useful method for inferior mobilization of the superior tracheal segment and can be done under cervicotomy [5]. In this case, suprahyoid release was omitted because superior mobilization of the distal trachea is more important than inferior mobilization of the upper trachea to complete anastomosis under cervicotomy without sternotomy and the tension of anastomosis was not high after bilateral bronchial release. VAM al-

lows a good operative view and is a less invasive procedure for bilateral main bronchial release by a transcervical approach. Bilateral main bronchial release permits a sufficient length for anastomosis after long segmental resection without applying another release technique. In the present case, we were able to remove almost half of the trachea, and anastomosis could be completed without excessive tension. Postoperative computed tomography revealed 3-cm upward mobilization of the carina, which means that bilateral main bronchial release permitted removal of about 3 cm of the trachea. In conclusion, bilateral bronchial release with cervical VAM is feasible and is a less invasive modality for long segmental resection and anastomosis of the trachea.

REFERENCES

1. Mulliken JB, Grillo HC. *The limits of tracheal resection with primary anastomosis: further anatomical studies in man*. J Thorac Cardiovasc Surg 1968;55:418-21.
2. Maeda M, Grillo HC. *Effect of tension on tracheal growth after resection and anastomosis in puppies*. J Thorac Cardiovasc Surg 1973;65:658-68.
3. Watanabe S, Takagi K, Nakamura Y, Sakata R. *Tracheal release and thymus wrapping of the tracheoplasty anastomosis through mini-sternotomy*. Eur J Cardiothorac Surg 2004;25: 287-9.
4. Pop D, Venissac N, Leo F, Mouroux J. *Video-assisted mediastinoscopy: a useful technique for paratracheal mesothelial cysts*. J Thorac Cardiovasc Surg 2005;129:690-1.
5. Montgomery WW. *Tracheal stenosis*. In: Montgomery WW, editor. *Surgery of the larynx, trachea, esophagus and neck*. Philadelphia: Saunders. 2001;234-9.