



Rapid communication

Intermuscular pocket for subcutaneous implantable cardioverter defibrillator: Single-center experience

Paola Ferrari, MD, Fabrizio Giofrè, MD, Paolo De Filippo, MD*

Cardiac Electrophysiology and Pacing Unit, Azienda Ospedaliera Papa Giovanni XXIII, Bergamo 24127, Italy

ARTICLE INFO

Article history:

Received 15 September 2015

Received in revised form

8 January 2016

Accepted 19 January 2016

Available online 23 February 2016

Keywords:

Subcutaneous implantable cardioverter defibrillator

ABSTRACT

The subcutaneous implantable cardioverter defibrillator (S-ICD) is a novel device now accepted in clinical practice for treating ventricular arrhythmias. In 14 consecutive patients, S-ICD devices were placed in the virtual space between the anterior surface of the serratus anterior muscle and the posterior surface of the latissimus dorsi muscle. During a mean follow up of 9 months, no dislocations, infections, hematoma formations, or skin erosions were observed. Intermuscular implantation of the S-ICD could be a reliable, safe, and appealing alternative to the standard subcutaneous placement.

© 2016 Japanese Heart Rhythm Society. Published by Elsevier B.V. This is an open access article under the CC BY-NC-ND license (<http://creativecommons.org/licenses/by-nc-nd/4.0/>).

1. Introduction

The implantable cardioverter defibrillator (ICD) is a universally accepted, evidence-based treatment for the prevention of sudden cardiac death [1]. However, the transvenously implanted endocardial lead still represents the weakest link in the ICD technology, as it is the source of most mechanical complications and is associated with an increased risk of bacteremia and endocarditis infection [2–4]. Recently, a new and totally subcutaneous defibrillator (S-ICD), that leaves the heart and vessels completely “untouched”, has been introduced into clinical practice [5,6]. A recent meta-analysis demonstrated that the most common procedure-related complications for this device were limited to the pocket: infection, hematoma, and skin erosion [7].

One shortcoming of the S-ICD is that the generator size is larger than that of the transvenous ICD (T-ICD), as it requires a larger battery and larger capacitors to deliver a higher energy shock during life-threatening arrhythmias. Today, the standard implanted position of the S-ICD involves a subcutaneous pocket created over the fifth intercostal space between the mid and anterior axillary lines [8].

Patients with low body mass index, depleted fat stores, and insufficient subcutaneous tissue to adequately cover the S-ICD device are at risk of inadequate incision site healing. In this setting, intermuscular implantation could be an appealing alternative to a subcutaneous pocket. In young patients, intermuscular device placement could offer the potential advantages of a better

cosmetic outcome and prevention of device damage during games and physical activities.

2. Materials and methods

For surgical purposes, we can divide the target zone wall into three planes. The first plane is composed of skin and subcutaneous tissue; the second is a muscular superficial plane composed of the latissimus dorsi muscle with its fascia; the third plane, a deep muscular plane, is composed of the serratus anterior muscle and its fascia.

The latissimus dorsi muscle is the largest muscle in the back. The muscle originates along the T7 region of the spine and extends to its insertion point on the humerus, specifically at the bicipital groove. The serratus anterior muscle includes three digitations that cover the medial wall of the axilla and penetrate deep to the scapula to insert into its medial border. Intermuscular implantation places the S-ICD in the virtual space between the anterior surface of the serratus anterior muscle and the posterior surface of the latissimus dorsi muscle.

The procedures were performed in an electrophysiology laboratory under standard sterile conditions and were carried out during general anesthesia. After anesthesia induction, the patient's head and left arm were positioned to facilitate the surgery and to promote sterility. Abduction of the left arm (60°) improved pocket access and ensured that the generator was seated in the appropriate location. Slight right rotation of the head allowed sterile draping over the manubrium and sternum and facilitated tunneling of the parasternal electrode into its upper location. Before sterile draping, a dummy of the S-ICD and lead were secured on the patient's chest by adhesive plaster. The positioning of both was

* Corresponding author. Tel.: +39 035 267 3557; fax +39 035 267 4965.

E-mail address: pdefilippo@hpg23.it (P. De Filippo).

guided by anatomical landmarks, as suggested in the manufacturer User's Manual [8], with the pocket at the fifth intercostal space between the mid and anterior axillary lines and the lead 1–2 cm to the left of the sternal midline. The position of the lead and S-ICD relative to the heart silhouette was checked by fluoroscopy. Finally, the lead and S-ICD position were drawn onto the chest with a demographic marker pen demographic pen, as well as the incision line for the pocket creation along the chest Langer's lines.

For the pocket, a 6 cm incision was made along the predefined Langer's lines. Subcutaneous dissection was carried out using an electrosurgical cutting and coagulation device, parallel to the incision, down to the fascia overlying the latissimus dorsi muscle (shining transparent membrane).

Intermuscular implantation places the S-ICD in the virtual space between the latissimus dorsi and serratus anterior muscles (Fig. 1). This area may be accessed with scissors by a blunt dissection, parallel to the vertical latissimus dorsi muscle fibers. When the serratus anterior is reached, it is important to recognize the change in the fiber pathway, horizontal versus vertical, so that the muscular fascia may be preserved in order to minimize bleeding. The pocket was formed over the serratus anterior muscular fascia and beneath the latissimus dorsi muscle by detaching the fibrous tissue between the muscles.

Electrode positioning was performed following the two-incision technique described by Knops and co-workers [9]. Once the electrode was connected to the generator and the latter was seated in the pocket, two separate non-absorbable sutures were inserted through the connector block suture portal and a suture knot was tied to anchor the S-ICD to the latissimus dorsi muscle, preventing both device migration and rotation.

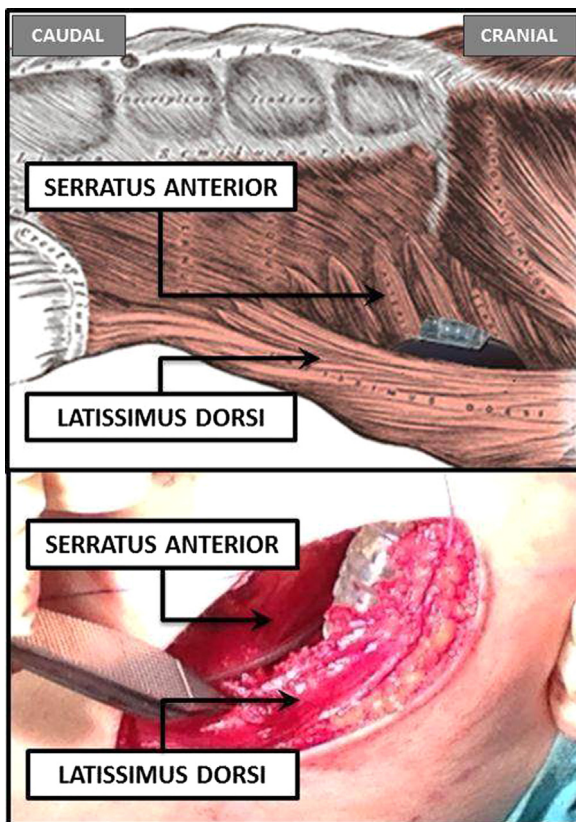


Fig. 1. Intermuscular implantation places the S-ICD pulse generator in the virtual space between the anterior surface of the serratus anterior muscle and the posterior surface of the latissimus dorsi muscle, over the left sixth rib between the mid and anterior axillary lines.

Table 1

Characteristics of patients implanted with a subcutaneous ICD using the intermuscular technique ($n=14$).

Male	12
Age at implant	47 ± 14 years (range 21–66)
Body mass index	24 ± 3 kg/m ²
Clinical disease	
Ischemic cardiomyopathy	6
Non-ischemic cardiomyopathy	3
Channelopathies	1
Hypertrophic cardiomyopathy	2
Idiopathic VF	2
Left ventricular ejection fraction indication	42 ± 14% (range 30–65%)
Primary prevention	12
Secondary prevention	2

VF=ventricular fibrillation.

3. Results

An S-ICD was implanted in 14 consecutive patients using the intermuscular pocket approach for device positioning. The characteristics of the patient population are displayed in Table 1. All patients underwent pre-implant screening using the only commercially available S-ICD pre-implant screening tool; all patients had at least two vectors suitable for S-ICD sensing (three vectors in 6 patients).

The implantations, including the defibrillation test (DFT), were each performed within 60 minutes (55 ± 12 min). The DFT was performed after the generator had been positioned in the pocket and the pocket closed completely. The most time-consuming step was the closing of the wound to ensure optimal cosmetic results. No specific bleeding issues were encountered during the procedures.

In all patients, the DFT was performed at 65 J after induction of ventricular fibrillation (VF) by 50-Hz burst stimulation. The DFT was deemed successful if the device detected and converted the ventricular tachycardia (VT) or VF into sinus rhythm using 65-J standard polarity. During VF conversion testing, all 14 episodes of induced VT or VF resulted in accurate arrhythmia detection and termination with a shock energy ≤ 65 J and with mean time to therapy of 15.1 ± 2.2 s (range 12–19 s). After implantation, all patients had at least two vectors suitable for S-ICD sensing based on the S-ICD software algorithm. No significant differences were found in terms of vector suitability determined by the pre-implant screening tool (ECG screening) and the S-ICD software algorithm.

During a mean follow up of 9 months (range 3–12 months), no dislocations of either the S-ICD pulse generator or the electrode were observed on routine chest X-rays obtained 1 day and 2 months after implantation. One patient reported mild discomfort from the S-ICD pocket during the first week after implantation. This discomfort resolved spontaneously and did not necessitate pocket revision. No infections, hematoma formations, or skin erosions occurred during the follow up. All device parameters were in range; in particular, no difference was found in terms of vector suitability for S-ICD sensing. All patients were comfortable with the position and appearance of the device (Figs. 2 and 3).

No patient experienced appropriate or inappropriate shocks. In one patient, a short interval of T-wave oversensing caused the device to falsely register an episode of non-sustained VT; however, after the S-ICD was reprogrammed to a different vector, no other over-sensing episodes were recorded.

4. Discussion

In our pilot experience the intermuscular pocket approach ensured safe and efficient healing of the incision site. This may prevent pocket-related complications, while resulting in a better

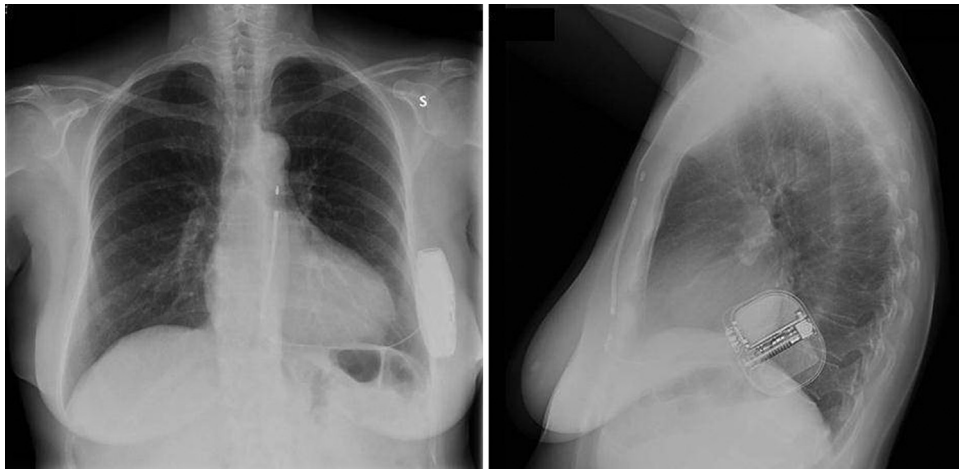

Fig. 2. Postoperative chest radiography, anteroposterior view and lateral view, confirming the final position of the lead and S-ICD pulse generator.

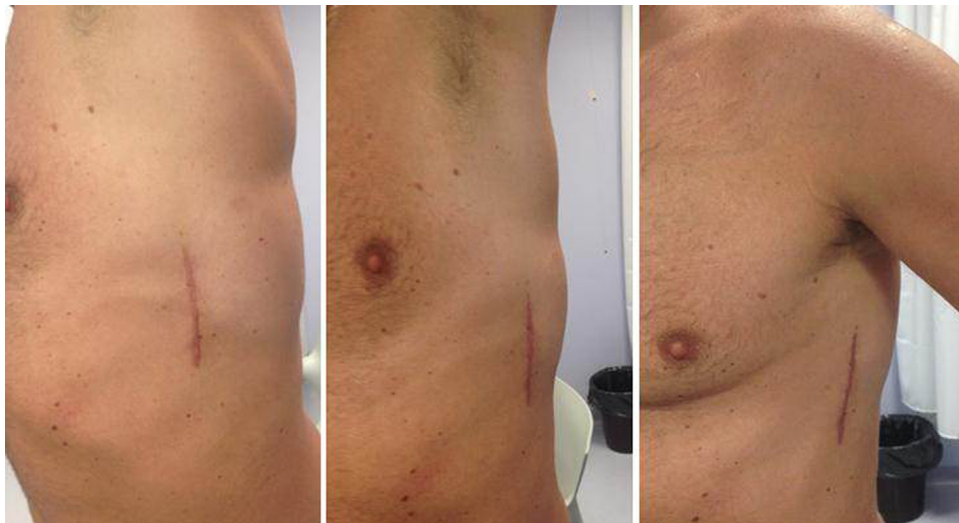

Fig. 3. Patient with intermuscular implantation of S-ICD pulse generator. The pictures show complete healing of the wound and effective concealment of the device.

cosmetic effect and allowing better device concealment. It seems likely that the favorable results in terms of infections, hematoma formation, or skin erosion will be maintained during long-term follow up because, as shown in FDA Investigational Device Exemption (IDE) and EFFORTLESS registry data, 40% of total complications with the S-ICD system occur within the first 30 days.

The footprint of the currently available S-ICD devices might increase the risk of pocket complications, particularly in patients who lack sufficient subcutaneous tissue to cover the device adequately. Moreover, the bulge created by the pulse generator could be cosmetically disturbing, especially for young patients. In our previous experience using the standard implantation technique, the bulge was generally perceived as more evident.

In this pilot study we described an intermuscular pocket approach that might be a reliable and safe alternative for S-ICD pulse generator positioning. The technique had a 100% implantation success rate in 14 patients and no infections, hematoma formations, or skin erosions occurred during the follow up. Additionally, there were no substantial procedure-related sensing issues: only one patient had a short episode of T-wave oversensing, which was eliminated by reprogramming of the S-ICD to a different vector.

Because of the absence of appropriate or inappropriate shocks in our series of patients, we have no data about the arrhythmia

termination efficacy during spontaneous VT/VF. Based on the high rate of DFT efficacy (100% at implantation), we may expect shock conversion efficacy during spontaneous arrhythmia events to be at least comparable with the efficacy rates reported in previous published studies [5–7]. Moreover, the nearer to the heart the pulse generator is placed, the more the shock vector efficacy might be improved. With the intermuscular pocket approach, the S-ICD is nearer to the heart than it is in the conventional subcutaneous approach.

Submuscular pocket positioning for transvenous device implantation is a widespread approach. The potential increase in both procedural time and patient pain at the time of generator exchange has not reduced its application. This is because the use of the submuscular pocket has acknowledged benefits for particular patients, such as young patients and/or those with a low body mass index. We believe the same applies to the intermuscular pocket approach for S-ICD implantation; thus, the previously outlined advantages make a cost-benefit analysis more favorable to intermuscular implantation than to the standard subcutaneous approach.

5. Conclusions

The intermuscular pocket approach may be a reliable and safe alternative for S-ICD pulse generator positioning. This technique

might lead to better incision site healing, reduce pocket-related complications, and offer a better cosmetic effect and device concealment. Of course, long-term data on a larger patient population will be needed to establish the superiority of this technique compared to the standard one.

Conflict of interest

None of the authors has any conflict of interest with respect to this study.

References

- [1] Priori SG, Blomström-Lundqvist C, Mazzanti A, et al. ESC Guidelines for the management of patients with ventricular arrhythmias and the prevention of sudden cardiac death: The Task Force for the Management of Patients with Ventricular Arrhythmias and the Prevention of Sudden Cardiac Death of the European Society of Cardiology (ESC) Endorsed by: Association for European Paediatric and Congenital Cardiology (AEPC). *Europace* 2015;2015(17):1601–87.
- [2] Kleemann T, Becker T, Doenges K, et al. Annual rate of transvenous defibrillation lead defects in implantable cardioverter-defibrillators over a period of > 10 years. *Circulation* 2007;115:2474–80.
- [3] Sohail MR, Henrikson CA, Braid-Forbes MJ, et al. Mortality and cost associated with cardiovascular implantable electronic device infections. *Arch Intern Med* 2011;171:1821–8.
- [4] Voigt A, Shalaby A, Saba S. Continued rise in rates of cardiovascular implantable electronic device infections in the United States: temporal trends and causative insights. *Pacing Clin Electrophysiol* 2010;33:414–9.
- [5] Weiss R, Knight BP, Gold MR, et al. Safety and efficacy of a totally subcutaneous implantable-cardioverter defibrillator. *Circulation* 2013;128:944–53.
- [6] Bardy GH, Smith WM, Hood MA, et al. An entirely subcutaneous implantable cardioverter-defibrillator. *N Engl J Med* 2010;363:36–44.
- [7] Burke MC, Gold MR, Knight BP, et al. Safety and efficacy of the totally subcutaneous implantable defibrillator. 2-Year results from a pooled analysis of the IDE Study and EFFORTLESS Registry. *J Am Coll Cardiol* 2015;65:1605–15.
- [8] Knops RE, Olde Nordkamp LR, de Groot JR, et al. Two-incision technique for implantation of the subcutaneous implantable cardioverter-defibrillator. *Heart Rhythm* 2013;10:1240–3.
- [9] SQ-RX[®] pulse generator. A component of the S-ICD[®] system. User's manual. Model 1010. San Clemente, (CA, USA): Cameron Health Inc. Available from: <http://www.fda.gov/downloads/AdvisoryCommittees/CommitteesMeetingMaterials/MedicalDevices/MedicalDevicesAdvisoryCommittee/CirculatorySystemDevicesPanel/UCM301239.pdf> ; 2016 [Accessed 22.01.16].