

Intravitreal anti-VEGF injection for the treatment of progressive juxtapapillary retinal capillary hemangioma: a case report and mini review of the literature

Elias Chelala
Ali Dirani
Ali Fadlallah

Saint-Joseph University, Faculty of Medicine, Beirut, Lebanon

Abstract: We report a case of a patient known to have a von Hippel–Lindau disease with documented progressive juxtapapillary retinal capillary hemangioma (JRCH) with well-preserved visual acuity (VA) and visual field (VF). The patient received a single injection of intravitreal ranibizumab (IVR). Six months after IVR injection, the JRCH showed reduced vascularization, fibrosis, and mild shrinkage, and VA and VF remained unchanged. IVR therapy might therefore be considered as an alternative treatment for progressive JRCH, especially in patients with well-preserved VA and VF.

Keywords: juxtapapillary retinal capillary hemangioma, intravitreal anti-VEGF injection, von Hippel–Lindau disease

Introduction

Retinal capillary hemangioma (RCH) is the most frequent manifestation of von Hippel–Lindau (VHL) disease.¹ RCHs are hamartomatous malformations most commonly detected in patients between ages 25 and 30 years.¹ They are located juxtapapillary in 17% of cases.¹ In general, juxtapapillary RCHs (JRCHs) are treated if they are progressive or if they affect visual acuity (VA).²

Herewith, we report a typical case of progressive JRCH that was successfully treated with a single injection of intravitreal ranibizumab (IVR).

Case

A 44-year-old man, known to have VHL disease was referred to our ophthalmology clinic for routine fundus examination in 2008. The patient had chronic renal failure after he underwent bilateral partial nephrectomy for renal cell carcinoma, and he also had spinal cord hemangioma diagnosed by spinal magnetic resonance imaging. On examination, his best corrected VA was 20/20 both eyes. Intraocular pressure was 12 mmHg right eye and 13 mmHg left eye. Results of slit-lamp examination of both eyes and fundus examination of the right eye were normal. Fundoscopy of the left eye revealed an exophytic juxtapapillary capillary hemangioma along the nasal margin of the disc. No serous retinal detachment or exudates were observed in the macular or peripapillary area (Figure 1A). Fluorescein angiography of the left eye showed early and late hyperfluorescence of the lesion with no leakage (Figure 2A). A computerized Humphrey automated perimeter (Humphrey–Zeiss, San Leandro, CA, USA) (program

Correspondence: Ali Fadlallah
Saint-Joseph University, Faculty of Medicine, Damascus Road, BP 17-5208
Mar Mikhaël, Beirut 1104-2020, Lebanon
Tel +961 | 7138 8893
Email fadlallah2000@hotmail.com

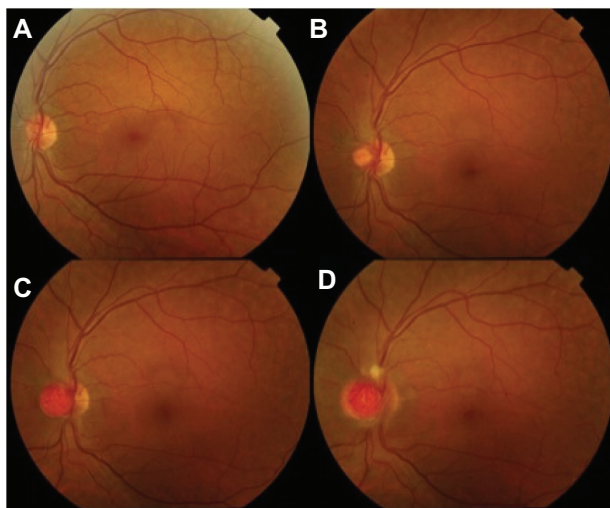


Figure 1 Fundus photos of the left eye show the progression of the juxtapapillary retinal capillary hemangioma in 2008 (A), 2010 (B), 2011 (C), and 2012 (D).

30-2) threshold test for visual field (VF) was normal in both eyes. No action was undertaken, and the patient was asked to return to the clinic yearly for follow-up.

On subsequent follow-up visits, we noticed a progressive increase in the size of the hemangioma, which in 2012 reached a diameter double that of the optic disc (Figure 1D). Also, some exudates and a minimal late leakage were observed in the peripapillary region on fluorescein angiography (Figure 2C). VA and VF remained unchanged. Due to the rapid increase in size of the JRCH, we decided to treat the patient with IVR. After detailed discussion with the patient, informed consent was received and IVR (0.5 mg ranibizumab; Lucentis, Genentech, Inc, San Francisco, CA, USA) was performed as an off-label treatment. Three weeks

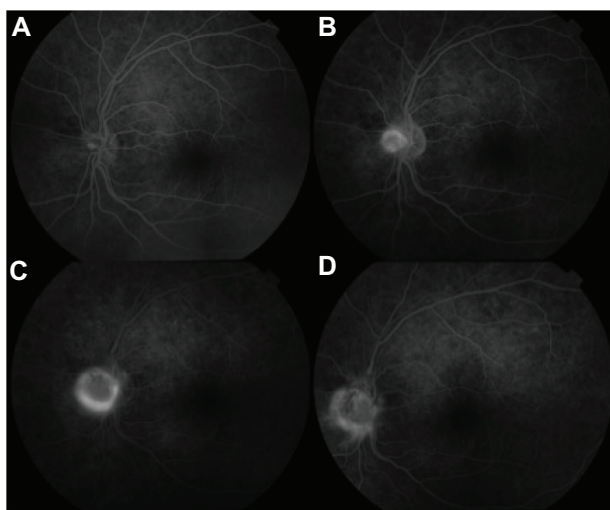


Figure 2 Fluorescein angiography of the left eye in 2008 (A), 2010 (B), 2012 (C), and 2013, 6 months after the single intravitreal injection of ranibizumab (D).

after a single injection of IVR, vascular channels within the hemangioma became less prominent. Six months after the single IVR, fundus examination showed a fibrotic, yellow-white appearance as a result of tumor scarring, and only few vascular channels could be seen within the hemangioma (Figure 3). Fluorescein angiography revealed a decrease in the vessels within the hemangioma and a decrease in late leakage (Figure 2D). During all follow up visits, VA remained unchanged. After IVR, there was no further increase in hemangioma size, no significant systemic or ocular adverse events associated with IVR were noted, and no additional injections were needed.

Discussion

Most RCHs show slow progression over time, but a small percentage may regress spontaneously. If RCHs enlarge over time and are left untreated, risk of exudation and subretinal fluid accumulation, cystoid macular edema, and retinal detachment increase, which can lead to progressive visual loss.²

The goal in the treatment of RCH is preservation of VA and the VF without destruction of the function of the retina around the tumor. Treatment depends on the size and location of the hemangioma and the clinical manifestations.²

Treatment strategies for JRCH change from observation to laser coagulation, radiation therapy, transpupillary thermotherapy, vitreoretinal surgery, and photodynamic therapy (PDT). In addition, juxtapapillary lesion therapies are often recalcitrant to treatment and the visual outcome of RCH after treatment varies.³

In general, observation is chosen as the initial management of JRCH, as they behave differently from the peripheral

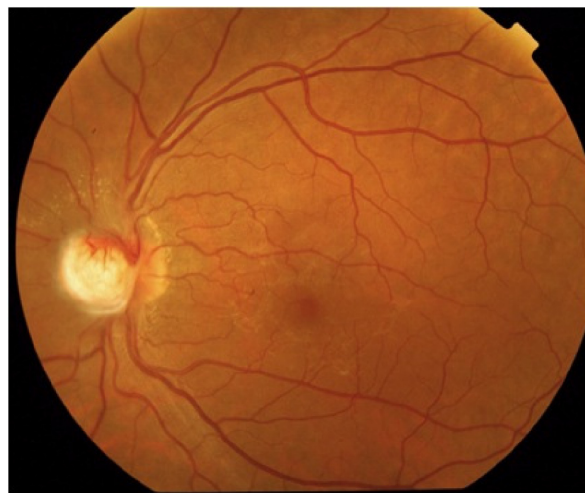


Figure 3 The fundus photo of the left eye in 2013, 6 months after the single intravitreal injection of ranibizumab, shows decreased vascularization of the hemangioma and mild fibrosis.

type of RCH. Some JRCHs have been noted to remain stable for years.^{1,2} The treatment of these lesions should only be undertaken if vision is reduced or if there is lesion progression, as treatment usually leads to significant reduction in acuity due to adverse effects on the optic nerve and major retinal vessels.²

Transpupillary thermoplasty has been used in the treatment of two reported cases of JRCH that resulted in complete fibrosis, although one case developed optic atrophy.¹ Laser photocoagulation applied to the neural tissue surrounding the tumor can cause permanent scotomas.² External radiation therapy has been shown to be effective in the treatment of optic disc hemangiomas,² but due to the posterior location of the tumor and its proximity to optic nerve, all these approaches are risky and can result in permanent VA deterioration or scotomas.

PDT was shown to be effective in causing fibrosis and involution of the primary angioma, but its use on the peripapillary area is limited by vaso-occlusive effects. For larger tumors, verteporfin may only be activated on the surface of the tumor, and the reactive oxygen species may not cause closure of deeper tumor vessels.⁴

Recent studies indicate that RCH may depend on vascular endothelial growth factor (VEGF), as patients with VHL disease who present with RCH have elevated ocular levels of anti-VEGF.⁵

Anti-VEGF therapy has been reported to reduce vascular permeability by altering the balance of vasoactive cytokines like nitric oxide and endothelin-1 or by directly altering endothelial tight junction proteins.⁶ It is postulated that excessive accumulation of hypoxia-induced factor in the neoplastic stromal cells of RCH leads to the production of other angiogenic factors that are able to maintain and promote the growth of primary hemangiomas.⁷

Many cases have been reported in which JRCHs were treated successfully with systemic administration of the anti-VEGF (VEGF-receptor inhibitor) SU5416, with a decrease in macular edema.⁷⁻⁹ It was believed that this treatment decreased the vasopermeability of the tumor, but the size of the tumor did not change.⁹ von Buelow reported one single case treated with systemic anti-VEGF treatment (bevacizumab) but with limited benefit. Moreover, the systemic treatment could be associated with severe side effects.¹⁰

Recent reports of combined therapy with anti-VEGF and PDT have shown promising results in these lesions.¹¹⁻¹³ Ziemssen et al reported a case of JRCH successfully treated with a single combination of intravitreal bevacizumab and PDT. The patient had marked regression of the hemangioma,

an increase in VA, regression of the scotoma on VF testing, and macular drying that persisted at the 1 year follow-up visit.¹¹ Mennel et al reported a patient with JRCH in the right eye that was associated with severe macular and peripapillary leakage.¹² The patient was treated with two sessions of PDT (sparing the part of the hemangioma located within the optic disc) and five injections of bevacizumab. In this single case, the combination of anti-VEGF and PDT appeared to be an effective strategy for the treatment of JRCH without side effects.¹² By combining anti-VEGF with reduced fluence PDT, the outline of the primary angioma can be better delineated and may thus reduce the energy and the treatment area, thereby minimizing the damage to the neurological tissues.¹³

Fong et al reported a patient with JRCH had associated macular edema and epiretinal membrane.¹³ The patient was treated with IVR injection and PDT 1 week before pars plana vitrectomy and epiretinal membrane peeling surgery. The use of this triple combined approach resulted in improvement of VA that remained stable at the 1 year follow-up visit.¹³

Recently, some researchers have applied intravitreal anti-VEGF therapy alone for the treatment of RCH. Ach et al reported the outcome of intravitreal bevacizumab for a RCH located in the midperiphery.¹⁴ A total of nine injections (administered every 13–14 weeks) of 2.5 mg bevacizumab were given intravitreally in the left eye over a period of 26 months. Repeated intravitreal injections of bevacizumab stopped the growth of the present RCH and perhaps inhibited the development of new hemangiomas in the treated eye. This is supported by the observation of ongoing growth of hemangiomas in the kidney, brain, and untreated fellow eye.¹⁴ Dahr et al reported two patients with juxtapapillary or large peripheral angiomas secondary to VHL who were treated with intravitreal injections of pegaptanib (3 mg/100 μ L), given every 6 weeks for minimum of six injections per patient. One of these two patients had improvement in VA, but no significant change in fluorescein leakage or tumor size was detected in either patient. The follow-up was at 1 year, and some adverse effects (hypotony and tractional retinal detachment) were reported.¹⁵

In our case, the patient had a progressive JRCH with no associated leakage or exudates. We performed a single IVR in order to halt the progression of JRCH and prevent all possible complications. Ranibizumab likely inhibited VEGF in and around the tumor and also suppressed permeability via the blockage of VEGF. Also, IVR seems to have the advantage of a decreased potential for retinal damage compared with other treatments for JRCH. The patient was continuously

followed on a routine basis to assess any need for further IVR if any progression of JRCH was noted.

In conclusion, IVR treatment can be effective in the stabilization of JRCH resulting from VHL disease and in the prevention of the exudation of hemangiomas. IVR therapy might therefore be considered as an alternative treatment for progressive JRCH, especially in patients with normal VA. However, longer follow-up and greater numbers of cases are needed to confirm the effectiveness of IVR for progressive JRCHs.

Disclosure

The authors report no conflicts of interest in this work.

References

1. Singh AD, Shields CL, Shields JA. von Hippel–Lindau disease. *Surv Ophthalmol*. 2001;46(2):117–142.
2. Singh AD, Nouri M, Shields CL, Shields JA, Perez N. Treatment of retinal capillary hemangioma. *Ophthalmology*. 2002;109(10):1799–1806.
3. Magee MA, Kroll AJ, Lou PL, Ryan EA. Retinal capillary hemangiomas and von Hippel–Lindau disease. *Semin Ophthalmol*. 2006;21(3):143–150.
4. Schmidt-Erfurth UM, Kusserow C, Barbazetto IA, Laqua H. Benefits and complications of photodynamic therapy of papillary capillary hemangiomas. *Ophthalmology*. 2002;109(7):1256–1266.
5. Los M, Aarsman CJ, Terpstra L, et al. Elevated ocular levels of vascular endothelial growth factor in patients with von Hippel–Lindau disease. *Ann Oncol*. 1997;8(10):1015–1022.
6. Wang W, Dentler WL, Borchardt RT. VEGF increases BMEC monolayer permeability by affecting occludin expression and tight junction assembly. *Am J Physiol Heart Circ Physiol*. 2001;280(1):H434–H440.
7. Chew EY. Ocular manifestations of von Hippel–Lindau disease: clinical and genetic investigations. *Trans Am Ophthalmol Soc*. 2005;103:495–511.
8. Aiello LP, Edwards AR, Beck RW, et al; Diabetic Retinopathy Clinical Research Network. Factors associated with improvement and worsening of visual acuity 2 years after focal/grid photocoagulation for diabetic macular edema. *Ophthalmology*. 2010;117(5):946–953.
9. Girmens JF, Erginay A, Massin P, Scigalla P, Gaudric A, Richard S. Treatment of von Hippel–Lindau retinal hemangioblastoma by the vascular endothelial growth factor receptor inhibitor SU5416 is more effective for associated macular edema than for hemangioblastomas. *Am J Ophthalmol*. 2003;136(1):194–196.
10. von Buelow M, Pape S, Hoerauf H. Systemic bevacizumab treatment of a juxtapapillary retinal haemangioma. *Acta Ophthalmol Scand*. 2007;85(1):114–116.
11. Ziemssen F, Voelker M, Inhoffen W, Bartz-Schmidt KU, Gelissen F. Combined treatment of a juxtapapillary retinal capillary haemangioma with intravitreal bevacizumab and photodynamic therapy. *Eye (Lond)*. 2007;21(8):1125–1126.
12. Mennel S, Meyer CH, Callizo J. Combined intravitreal anti-vascular endothelial growth factor (Avastin) and photodynamic therapy to treat retinal juxtapapillary capillary haemangioma. *Acta Ophthalmol*. 2010;88(5):610–613.
13. Fong AH, Li KK, Wong D. Intravitreal ranibizumab, photodynamic therapy, and vitreous surgery for the treatment of juxtapapillary retinal capillary hemangioma. *Graefes Arch Clin Exp Ophthalmol*. 2011;249(4):625–627.
14. Ach T, Thiemeier D, Hoeh AE, Schaal KB, Dithmar S. Intravitreal bevacizumab for retinal capillary haemangioma: longterm results. *Acta Ophthalmol*. 2010;88(4):e137–e138.
15. Dahr SS, Cusick M, Rodriguez-Coleman H, et al. Intravitreal anti-vascular endothelial growth factor therapy with pegaptanib for advanced von Hippel–Lindau disease of the retina. *Retina (Philadelphia, Pa)*. 2007;27(2):150–158.

Clinical Ophthalmology

Publish your work in this journal

Clinical Ophthalmology is an international, peer-reviewed journal covering all subspecialties within ophthalmology. Key topics include: Optometry; Visual science; Pharmacology and drug therapy in eye diseases; Basic Sciences; Primary and Secondary eye care; Patient Safety and Quality of Care Improvements. This journal is indexed on

Submit your manuscript here: <http://www.dovepress.com/clinical-ophthalmology-journal>

Dovepress

PubMed Central and CAS, and is the official journal of The Society of Clinical Ophthalmology (SCO). The manuscript management system is completely online and includes a very quick and fair peer-review system, which is all easy to use. Visit <http://www.dovepress.com/testimonials.php> to read real quotes from published authors.